

What is the Diagnosis?

CASE PRESENTATION

Patient T.D., 23 years old, female, with corrected transposition of the great arteries, complete atrioventricular block with narrow QRS (Fig. 1), submitted to bicameral pacemaker implantation at 13 years of age, with generator replacement three years ago. She has a good functional capacity, but complains of fatigue in the face of intense effort.

In the ergo spirometry test, from the sixth minute onwards (Figs. 2 and 3), the heart rate, which was previously determined by the pacemaker according to the patient's sinus frequency, dropped. The junctional rhythm determined the heart rate from this moment on with a frequency of 82 bpm (Fig. 4). In the recovery phase, the patient's rhythm was again determined by the pacemaker (Fig. 5). The initial questioning showed an episode of "atrial mode switch" at the moment of abrupt frequency drop (Fig. 6).

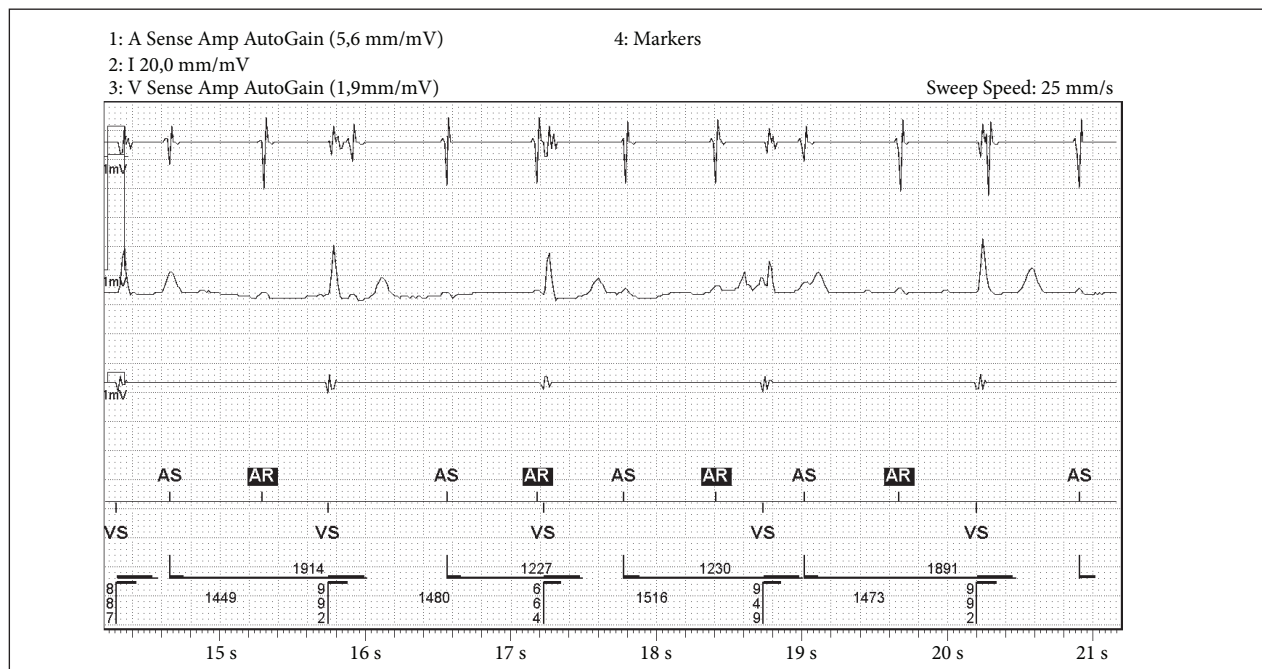


Figure 1. Basal electrocardiogram: sinus rhythm, complete atrioventricular block and ventricular escape rhythm with narrow QRS.

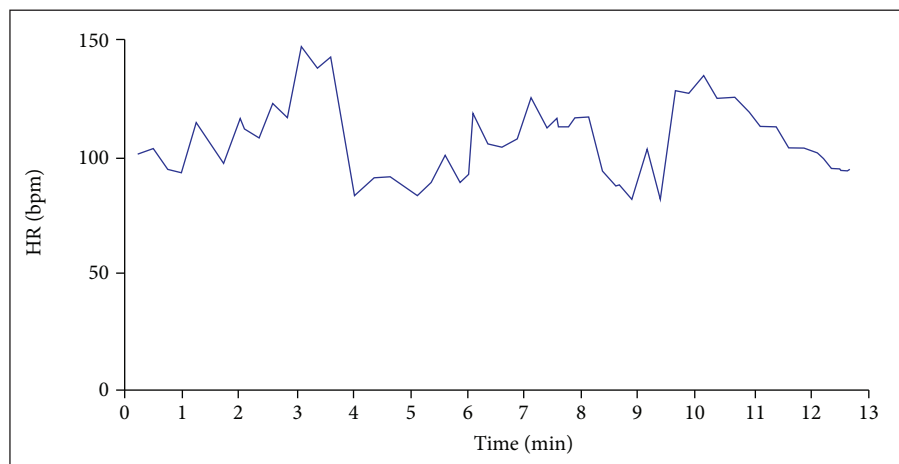


Figure 2. Graph of heart rate as a function of time in the ergo spirometry test.

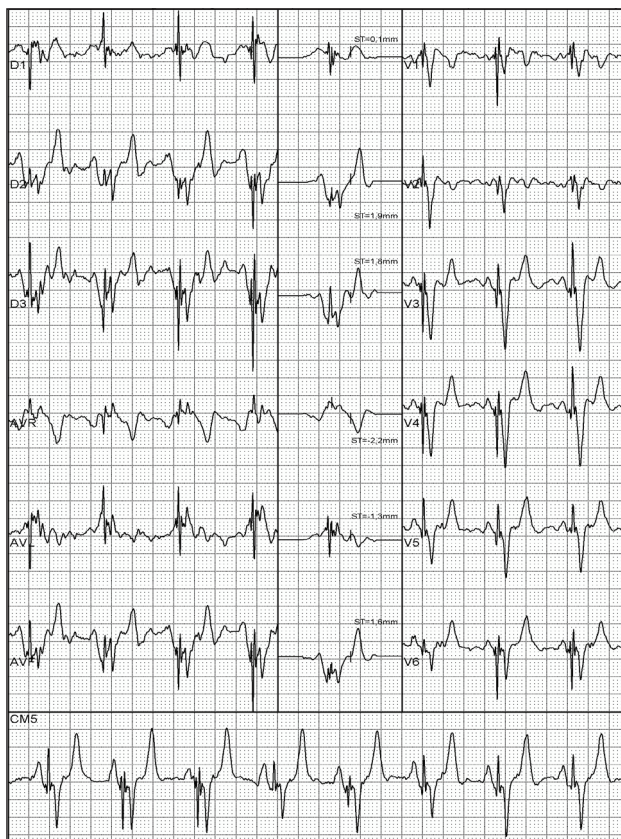


Figure 3. Ergospirometry test: recording at 4 min.

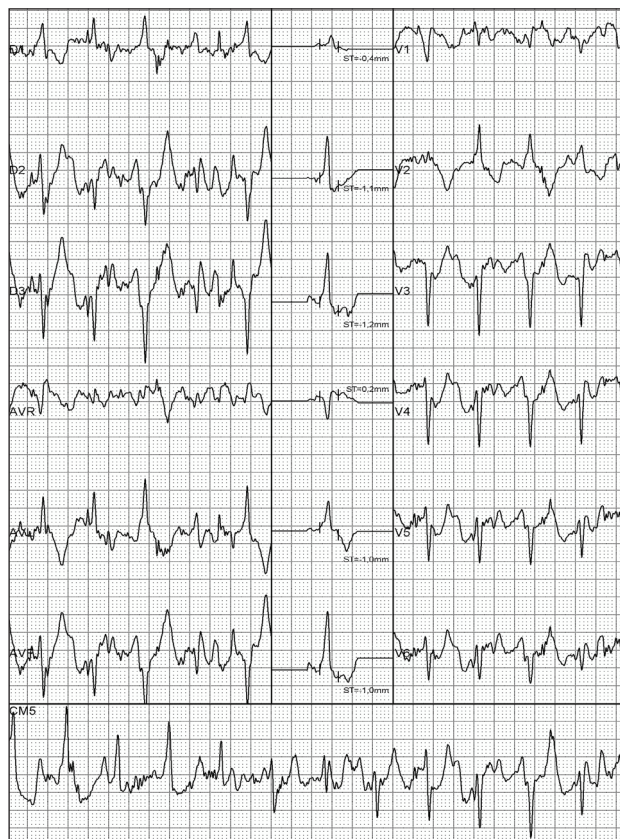

Figure 4. Ergospirometry test: recording at 6 min.

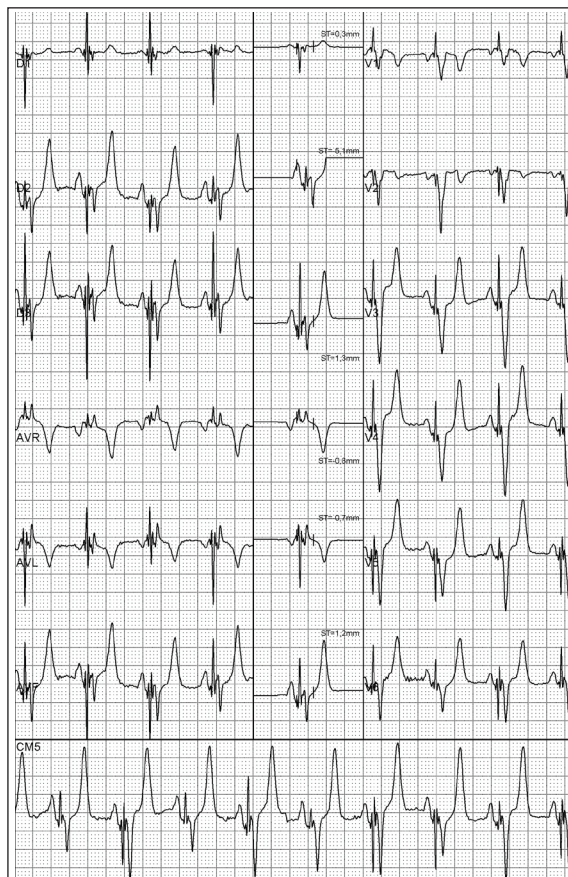


Figure 5. Ergospirometry test: recovery

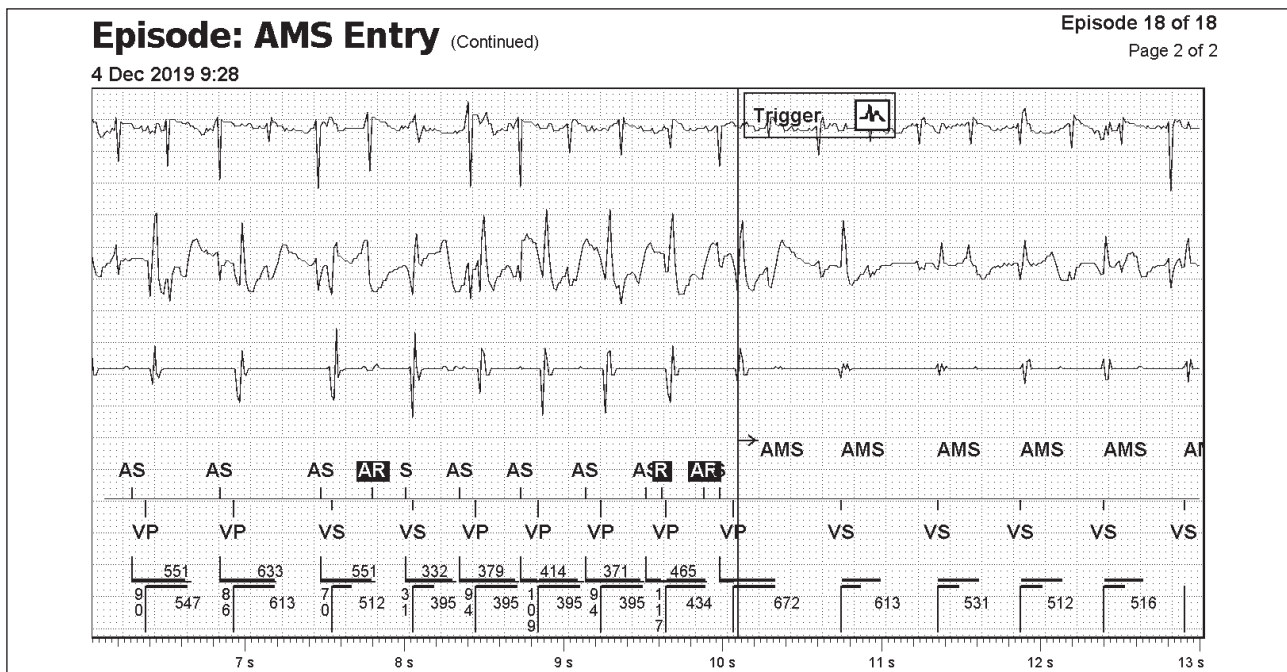


Figure 6. Telemetry: spurious activation of the “atrial mode switch” algorithm

CONCLUSION

Usually, the abrupt drop in atrial follow-up frequency in double chamber pacemakers occurs due to inadequate programming of maximum follow-up frequency or long atrial refractory periods. Specifically, in this case, the abrupt drop in the patient’s heart rate occurred due to the spurious activation of the “atrial mode switch” algorithm as a result of excessive sensitivity in the atrial channel, allowing the patient’s junctional rhythm to assume ventricular depolarization. The analysis of the electrocardiographic recording made by the pacemaker generator allowed accurate diagnosis.

REFERENCES

1. Ellenbogen KA, Wilkoff BL, Kay GN, Lau CP, Auricchio A. Clinical Cardiac Pacing Defibrillation, and Resynchronization Therapy. 5 Ed. Philadelphia: Elsevier; 2017.
2. Barold SS, Stroobandt RX, Sinnaeve AF. Cardiac Pacemakers Step by Step. Massachusetts: Blackwell Futura; 2004.

AUTHORS

Jose Mario Baggio Junior^{1,*}, Joubert Ariel Pereira Mosquera¹, Luis Gustavo Ferreira Gomes¹, Wagner Luis Gali¹, Alvaro Valentim Lima Sarabanda¹

Gali WL <https://orcid.org/0000-0002-8116-3009>

Sarabanda AVL <https://orcid.org/0000-0001-8053-4499>

1. Instituto de Cardiologia do Distrito Federal – Brasilia (DF), Brazil.

*Correspondence author: jmbaggio@cardiol.br