

Supraventricular Tachycardia Triggered after Central Venous Catheter Insertion

Alfredo Aurélio Marinho Rosa Filho^{1,*}, Caio Conde Merten¹, Dandara Dias Gomes da Cunha¹, Briane Alcântara Vieira Pasini², Carlos Romério Costa Ferro¹

ORCID ID

Rosa Filho AAM  <https://orcid.org/0000-0001-8060-221X>

Merten CC  <https://orcid.org/0000-0003-2663-7213>

Cunha DDG  <https://orcid.org/0000-0002-3136-817X>

Pasini BAV  <https://orcid.org/0000-0002-5058-4839>

Ferro CRC  <https://orcid.org/0000-0001-9341-2941>

ABSTRACT

Central venous access is an established procedure in clinical practice. A misplaced central venous catheter can induce supraventricular and ventricular arrhythmias. We describe the case of a 60-year-old female patient with a recent diagnosis of multiple myeloma hospitalized for chemotherapy. The patient had an episode of supraventricular tachycardia after installing a central venous catheter. The electrocardiogram of the case in question showed a RP' interval of 60 ms, corroborating the nodal reentry mechanism with the probable mechanism of tachycardia. The present report draws attention to the need for caution during the installation of these central venous catheters.

KEYWORDS: Arrhythmias, cardiac; Tachycardia, supraventricular; Central venous catheters.

INTRODUCTION

Central venous access is an established procedure in clinical practice routinely performed in intensive care units, emergency rooms, surgical centers and in wards¹.

The internal jugular, subclavian and femoral veins are the anatomical puncture sites routinely used, and the modified Seldinger technique is the most used methodology. Among the complications associated with central venous access, infections, venous stenosis or thrombosis, accidental arterial puncture, pneumothorax, hemothorax, and cardiac arrhythmias stand out².

A misplaced central venous catheter can induce both supraventricular and ventricular arrhythmias. The responsible mechanism is the mechanical stimulation of the catheter in the atrial or ventricular endocardium, resulting in an ectopic stimulus, which, if it occurs at any moment of electrical vulnerability, will induce arrhythmia³⁻⁷.

CASE REPORT

A 60-year-old female patient with a recent diagnosis of multiple myeloma was hospitalized for chemotherapy. The patient had no cardiovascular comorbidities. On admission, she had an electrocardiogram, electrolyte measurements and

1. Universidade Federal de Alagoas – Hospital Universitário Professor Alberto Antunes – Maceió (AL), Brazil.

2. Universidade Federal de São Paulo – São Paulo (SP), Brazil.

*Correspondence author: aamrosaf@gmail.com

Received: Aug 15, 2022 | Accepted: Nov 15, 2022



renal function that showed no abnormalities. She had a recent transthoracic echocardiogram, which showed only altered left ventricular relaxation.

Central venous puncture was performed in the right internal jugular vein, anterior access, using the Seldinger technique. The procedure was uneventful.

A few minutes after insertion of the catheter, the patient presented tachycardic palpitations, associated with general malaise and a sensation of beatings in the neck. At the time, she had a heart rate (HR) of 162 bpm and blood pressure of 138 × 72 mmHg.

At that moment, a 12-lead electrocardiogram (Fig. 1) was performed, which showed a tachycardic rhythm, with no visible P waves, narrow QRS complexes, regular R-R intervals, and RP' interval, best visualized in lead V1, in around 60 ms. She also performed a chest X-ray (Fig. 2), which showed the tip of the catheter inside the right atrium.

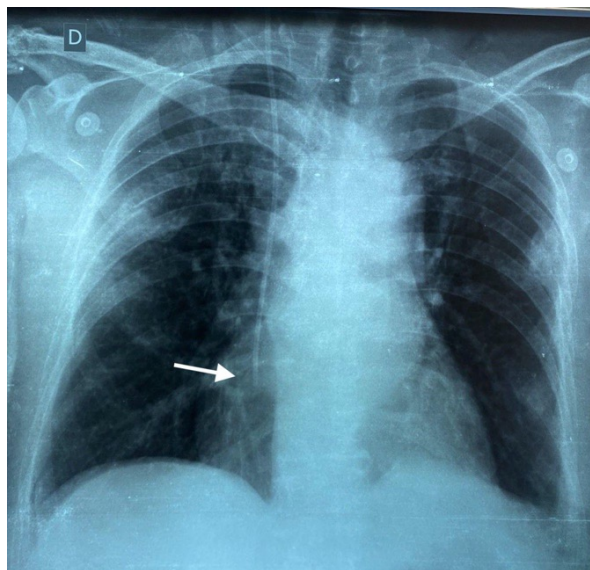


Figura 1. Chest X-ray in posteroanterior view. The arrow shows the tip of the venous catheter inside the right atrium.

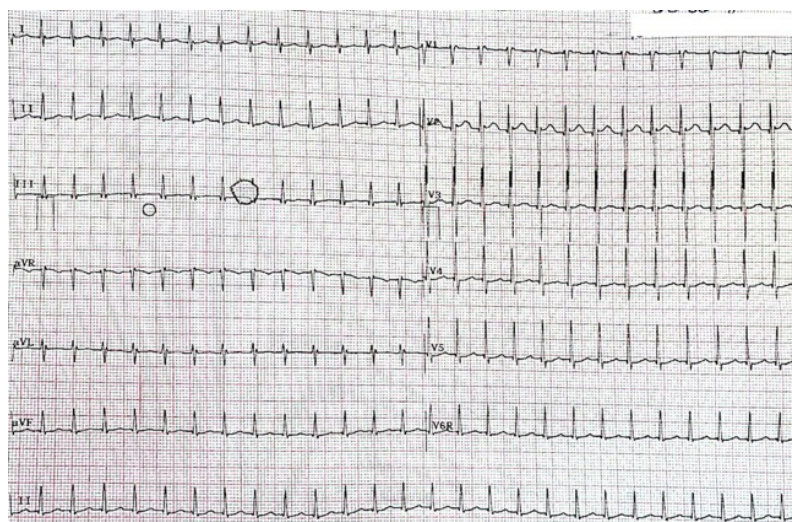


Figura 2. Electrocardiogram showing supraventricular tachycardia. The interval RP' measures 60 ms.

Vagal maneuvers (Valsalva and carotid sinus massage) were performed without success. Subsequently, adenosine was administered, with reversion to sinus rhythm after the second bolus (12 mg). At the time, it was decided to retreat the central catheter by approximately 2 cm. During the remainder of the hospital stay, the patient no longer had supraventricular tachycardia, remaining in sinus rhythm until discharge, when she was referred for outpatient evaluation with cardiology.

DISCUSSION

The present case consists of a 60-year-old female patient who had an episode of supraventricular tachycardia after installing a central venous catheter. The patient had no cardiac history.

Occasionally, central venous catheters may, when installed, be located inside the right atrium or, less frequently, the right ventricle. If mechanical contact between the catheter and the endocardial surface occurs, an ectopic stimulus can be generated, which will be responsible for triggering arrhythmias, ranging from isolated ectopic beats to sustained tachycardias⁷⁻⁹.

Supraventricular tachycardias are frequent arrhythmias, whose electrophysiological mechanism is usually reentry and requires the presence of an extra-stimulus as a trigger for the onset of tachycardia. Most often, this group of arrhythmias is represented by nodal reentry tachycardia (NRT) and atrioventricular reentry tachycardia (AVRT). In NRT, there is a functional and longitudinal dissociation of the atrioventricular node, resulting in two-conduction pathways with different electrophysiological properties (alpha and beta) that have different conduction times and refractory periods. In AVRT, the reentry circuit will use the atrioventricular node and an accessory pathway as stimulus conduction loops, one anterogradely and the other retrogradely¹⁰.

The patient's electrocardiogram recorded during tachycardia showed supraventricular tachycardia. In the electrocardiographic tracing, the analysis of the RP' interval, which corresponds to the time of retrograde conduction of the stimulus from the RV to the RA, can provide clues to the electrophysiological mechanism of tachycardia. This interval is comprised between the beginning of the QRS complex to the beginning of the retrograde P wave, best seen in D2 and V1. Tachycardias with a RP' interval shorter than 70 ms suggest that their electrophysiological mechanism is a nodal reentry. On the other hand, the RP' interval greater than 70 ms may be more frequently an atrioventricular reentry using an accessory pathway.

The electrocardiogram of the case in question showed a RP' interval of 60 ms, corroborating the nodal reentry mechanism with the probable mechanism of tachycardia.

The present report draws attention to the need for caution during the installation of these central venous catheters. Although there are no conclusive studies on the ideal positioning of the catheter tip, one should avoid introducing the catheter beyond what is necessary, considering the puncture site, jugular or subclavian, patient position and anatomical variations¹.

Furthermore, it is extremely important to know the possible complications that may occur, for the immediate diagnosis, approach, and resolution of the condition.

AUTHORS' CONTRIBUTION

Conceptualization: Rosa Filho AAM, Merten CC; **Formal Analysis, Writing – review & editing:** Rosa Filho AAM, Ferro CRC. **Methodology, Writing – original draft:** Rosa Filho AAM, Merten CC, Cunha DDG, Pasini BAV, Ferro CRC.

DATA AVAILABILITY STATEMENT

Data will be available upon request.

FUNDING

Not applicable.

ACKNOWLEDGMENTS

Not applicable.

REFERENCES

1. Frykholm P, Pikwer A, Hammarskjöld F, Larsson AT, Lindgren S, Lindwall R, et al. Clinical guidelines on central venous catheterisation. *Acta Anaesthesiol Scand*. 2014;58(5):508-24. <https://doi.org/10.1111/aas.12295>
2. Bevc S, Pecovnik-Balon B, Ekart R, Hojs R. Non-insertion-related complications of central venous catheterization: temporary vascular access for hemodialysis. *Ren Fail*. 2007;29(1):91-5. <https://doi.org/10.1080/08860220601039106>
3. Thyoka M, Haq I, Hosie G. Supraventricular tachycardia precipitated by a peripherally inserted central catheter in an infant with gastroschisis. *Case Reports*. 2014;2014:bcr2013201203. <https://doi.org/10.1136/bcr-2013-201203>
4. Huang Y-C, Huang J-C, Chen S-C, Chang J-M, Chen H-C. Lethal cardiac arrhythmia during central venous catheterization in a uremic patient: a case report and review of the literature. *Hemodial Int*. 2013;17(4):644-8. <https://doi.org/10.1111/hdi.12030>
5. Gabriels JK, Braunstein ED, Lerman BB, Thomas G, Cheung JW. Recurrent atrial tachycardias associated with implantable central venous access catheters in patients with cancer. *JACC Clin Electrophysiol*. 2021;7(11):1482-3. <https://doi.org/10.1016/j.jacep.2021.06.021>
6. Golamari R, Sedhai YR, Ramireddy K, Bhattacharya P. Atrial fibrillation induced by peripherally inserted central catheters. *Baylor University Medical Center Proceedings*. 2020;33(1):83-4. <https://doi.org/10.1080/08998280.2019.1668675>
7. Alvarez P, Schurmann P, Smith M, Valderrábano M, Lin CH. Position-dependent ventricular tachycardia related to peripherally inserted central venous catheter. *Methodist DeBakey Cardiovasc J*. 2016;12(3):177-8. <https://doi.org/10.14797/mdcj-12-3-177>
8. Flannery KR, Wilson SP, Manteuffel J. Ventricular tachycardia cardiac arrest during central line placement. *Am J Emerg Med*. 2016;34(1):114.e3-4. <https://doi.org/10.1016/j.ajem.2015.04.064>
9. Verdino RJ, Pacifico DS, Tracy CM. Supraventricular tachycardia precipitated by a peripherally inserted central catheter. *J Electrocardiol*. 1996;29(1):69-72. [https://doi.org/10.1016/S0022-0736\(96\)80116-6](https://doi.org/10.1016/S0022-0736(96)80116-6)
10. Josephson ME. Preexcitation syndromes. In: Josephson ME, ed. *Clinical Cardiac Electrophysiology*. 4th ed. Lippincott Williams & Wilkins; 2008.